



Art of Skin MD
Solana Beach, CA

Dermatologic Cosmetic Surgery III: Treatment of Leg Veins

ABCS Board Review

March 11, 2022

Melanie D. Palm, MD, MBA

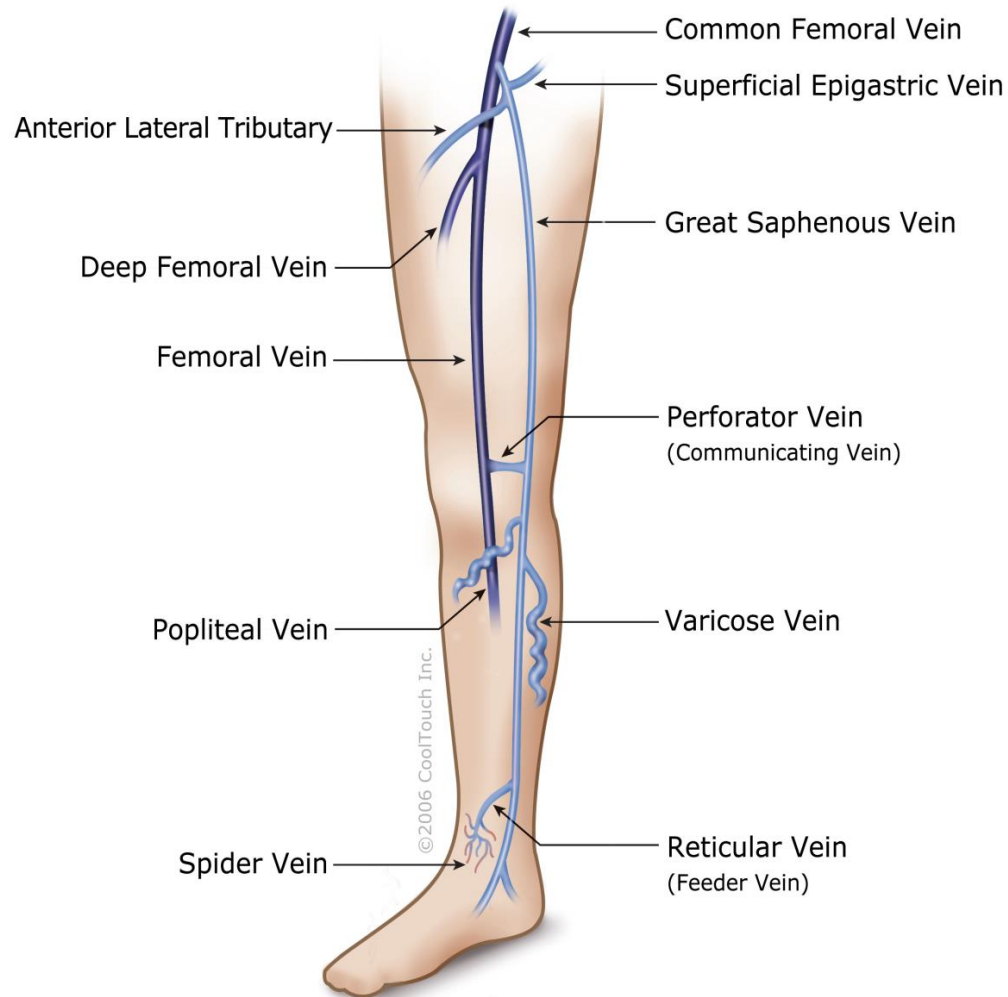
*Board-Certified Dermatologist
Fellowship-Trained Cosmetic Surgeon
Director, Art of Skin MD
Assistant Clinical Professor,
University of California, San Diego*

Topics for Discussion

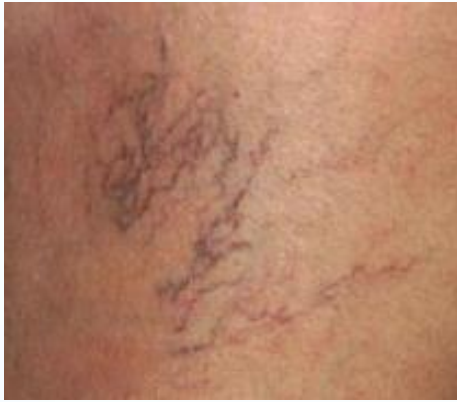- Basic vein anatomy
- Sclerotherapy
- Endovenous laser ablation

Vein Anatomy

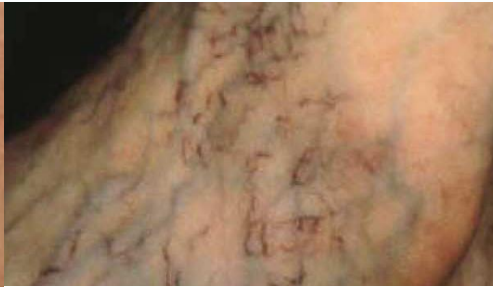Venous System



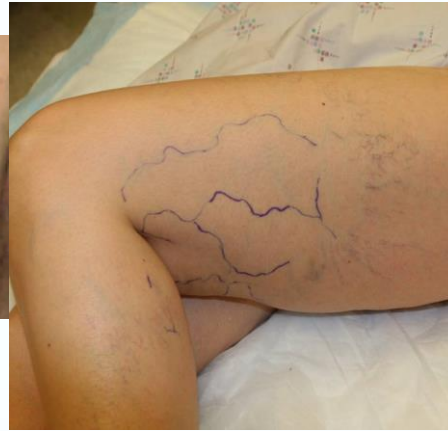Vein Categorization



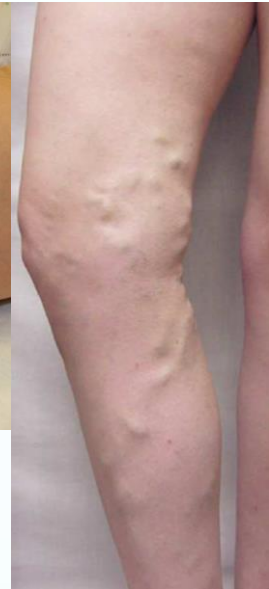Telangiectasias



Venulectasias

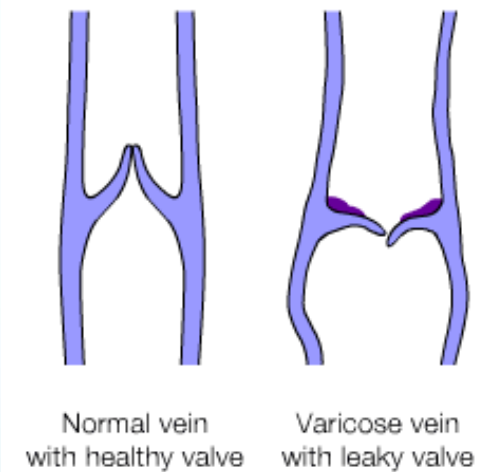
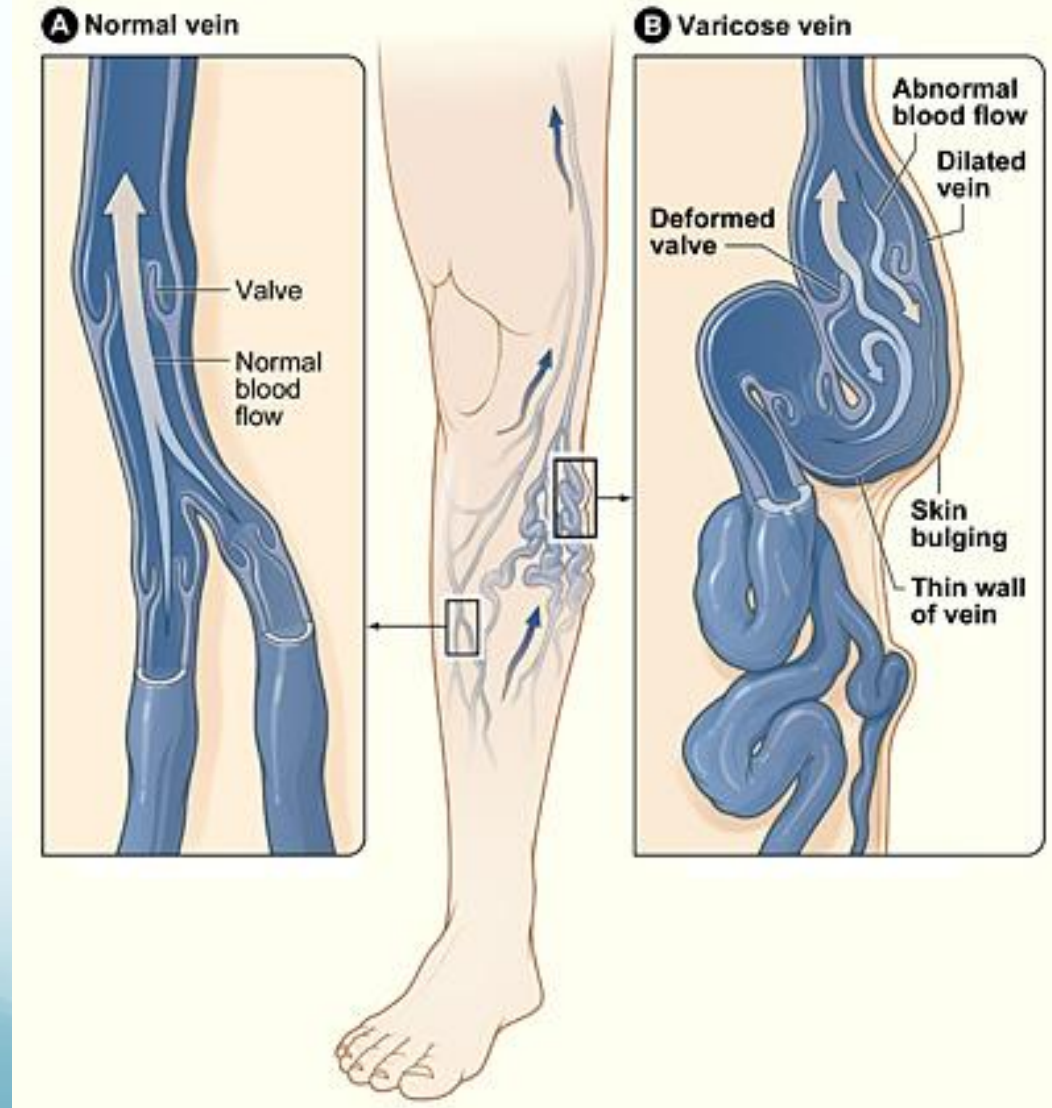


Reticular Veins



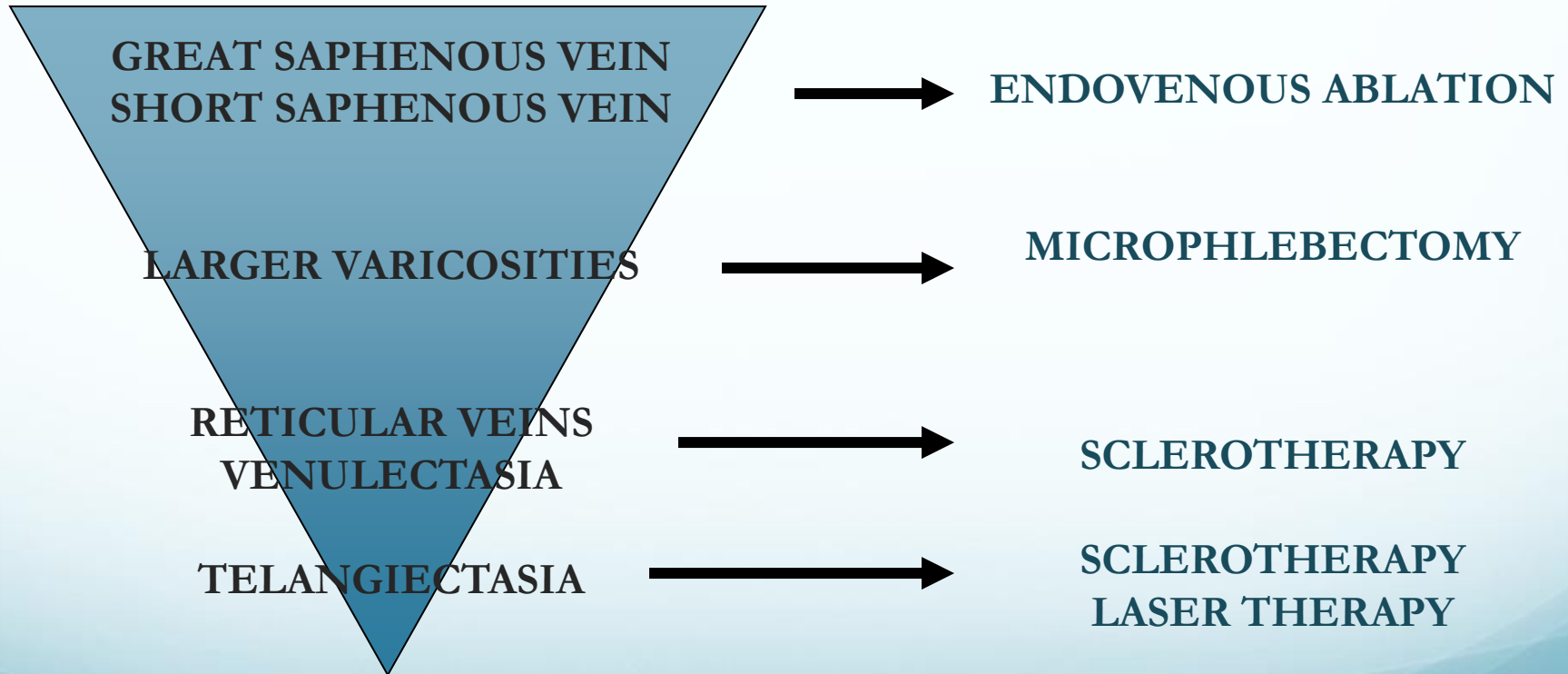
Varicose Veins

Leaky Valves = Varicose Veins



Treatment is Algorithmic

Everything is connected in a hierarchical way
Therapy must start from a top down approach



Sclerotherapy

Sclerotherapy: Introduction

- Injection of vessels with foreign substance, leading to vessel wall damage (endothelial damage), and subsequent vessel occlusion
- Vessel size is most significant prognostic factor in treatment success
- Sclerosants used:
 - Hypertonic saline (typically small vessels)
 - Glycerin (typically small diameter vessels, <1 mm)
 - Detergents (sodium tetradecyl sulfate, polidocanol)
 - Lower concentration for small vessels
 - Higher concentrations for larger vessels
- Complications
 - Pain, hyperpigmentation, telangiectatic matting, skin ulceration, urticaria, superficial thrombophlebitis, arterial injection (skin necrosis/slough + pain), nerve damage/paresthesias, migraines, DVT, PE, air embolism with foam (scintillating scotomata, TIA, CVA)

Hypertonic saline

- First used to sclerose varicose veins in 1920s
- MOA: osmotic agent—nonspecific destruction of all cells
- Advantages: no allergenicity
- Disadvantages:
 - **PAIN** at injection site
 - Nonspecific destruction of tissues → **ULCERATION**
 - Muscle cramps
 - Ineffective on varicose veins
- Maximum dose: 20 mL/session
- Application: telangiectasias, venulectasias

Glycerin

- Sugar solution, often prepared as 72% glycerin 2:1 with 1% lido with epi
- MOA: chemical irritant to vessel wall
- Advantages: Low incidence of side effects
 - Hyperpigmentation or skin necrosis exceedingly rare
- Disadvantages:
 - Local discomfort at injection site
- Maximum dose: 10 mL of pure solution
 - Overdose: hematuria
- Application: telangiectasias, venulectasias

Detergents: Sodium Tetradecyl Sulfate (STS) & Polidocanol

- Detergent, often foamed
- MOA: soap is destructive to endothelium
- Foam sclerotherapy (Tessari technique)
 - Allows lower effective concentration of sclerosant to be used
 - Extravasated foam better tolerated
 - Allows direct contact with endothelial wall
 - Displacement of blood, increased vasospasm
 - Easy identification of solution during procedure
- Disadvantage of Foam:
 - **Screen for PFO: visual disturbances, TIA/CVA**

Sodium Tetradecyl Sulfate (STS)

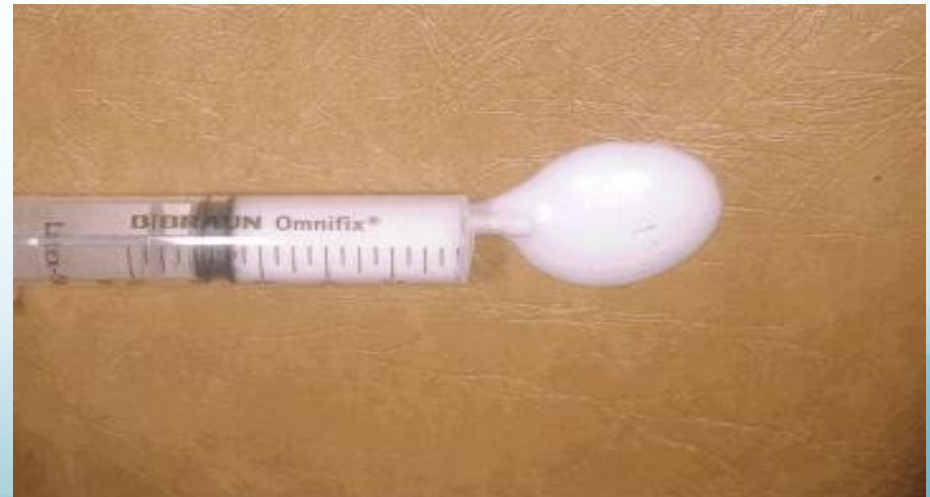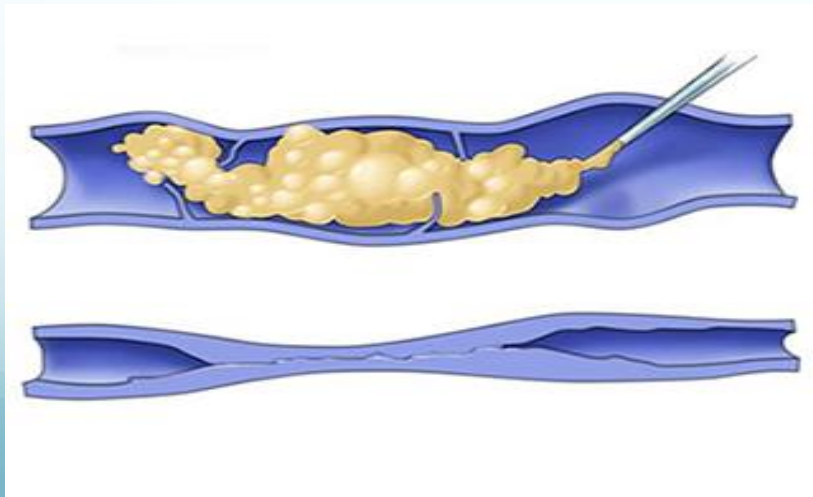
- FDA-approved in 1946 for varicose vein treatment
- Advantages:
 - Very mild discomfort on injection
- Disadvantages:
 - Solution is light-sensitive
 - **Foamed solution + PFO: visual disturbances, TIA, CVA**
 - **Skin ulceration** with solution extravasation
 - **Hyperpigmentation** with increasing concentrations
- Maximum dosage: 10 mL/session
- Clinical applications:
 - Larger veins at higher concentrations (1-3%)
 - Smaller reticular veins (0.25-0.5%)
 - Telangiectasias (0.1-0.3%)

Polidocanol

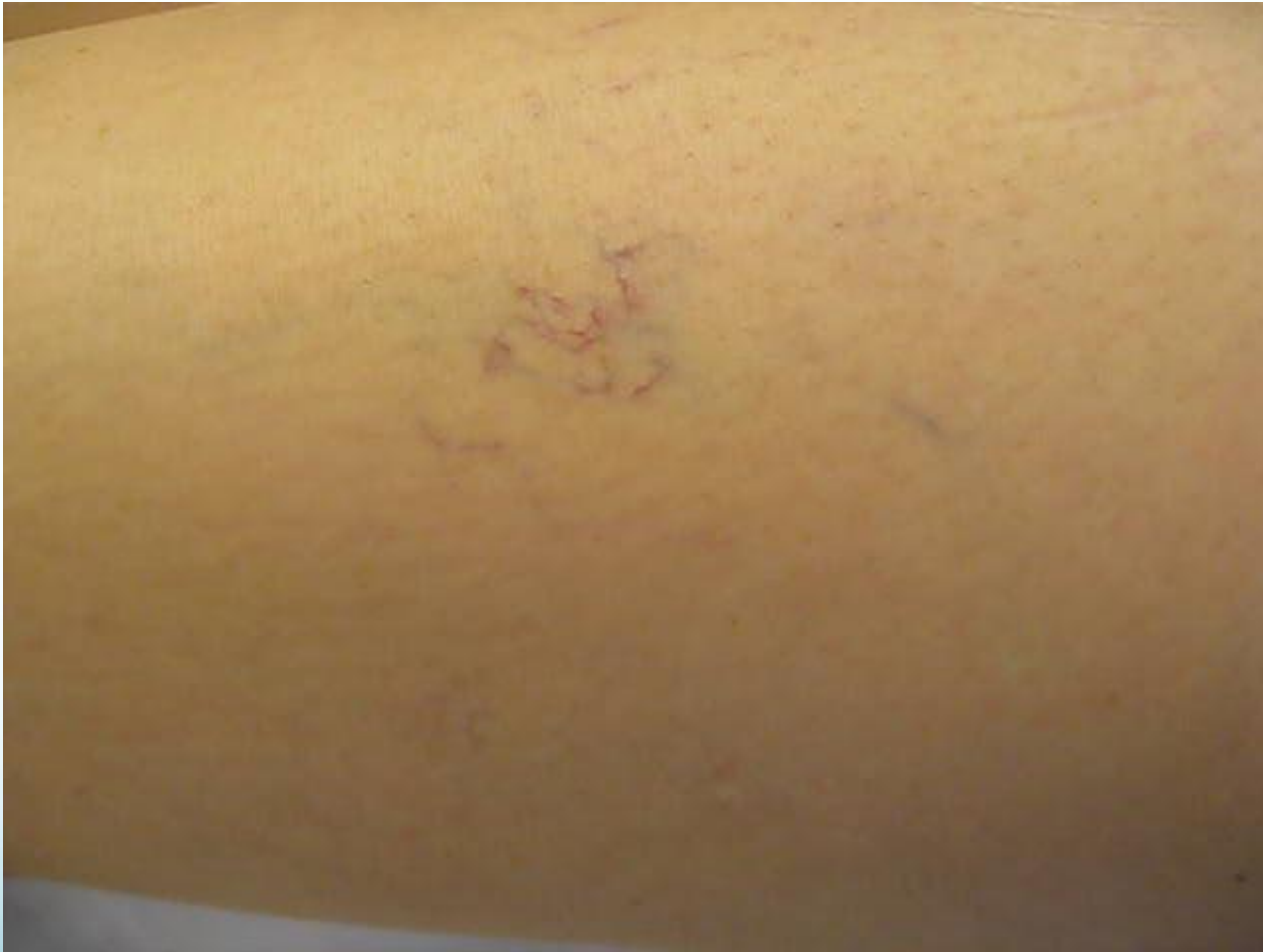- FDA-approved in 2010 for spider and reticular vein treatment
- Advantages:
 - Virtually painless injection—anesthetic effect of compound
 - Injected into skin without ulceration
 - Very low risk of hyperpigmentation
 - Low risk of allergic reaction
- Disadvantages:
 - **Foamed solution + PFO: visual disturbances, TIA, CVA**
 - Transient urticaria and pruritus
- Maximum dosage: less than 2 mg/kg per session (28 cc of 0.5% solution)
- Clinical applications:
 - Varicose veins (1-4% concentration)
 - Telangiectasias (0.25-0.75% concentration)

Foam Sclerotherapy

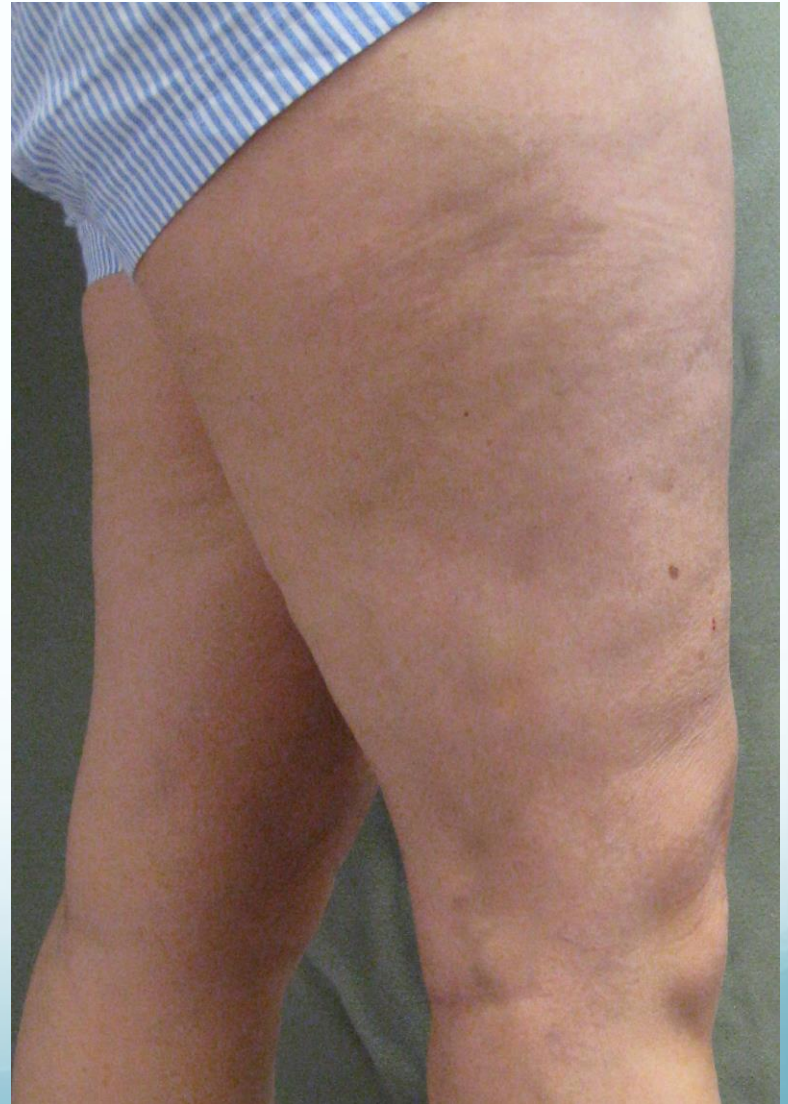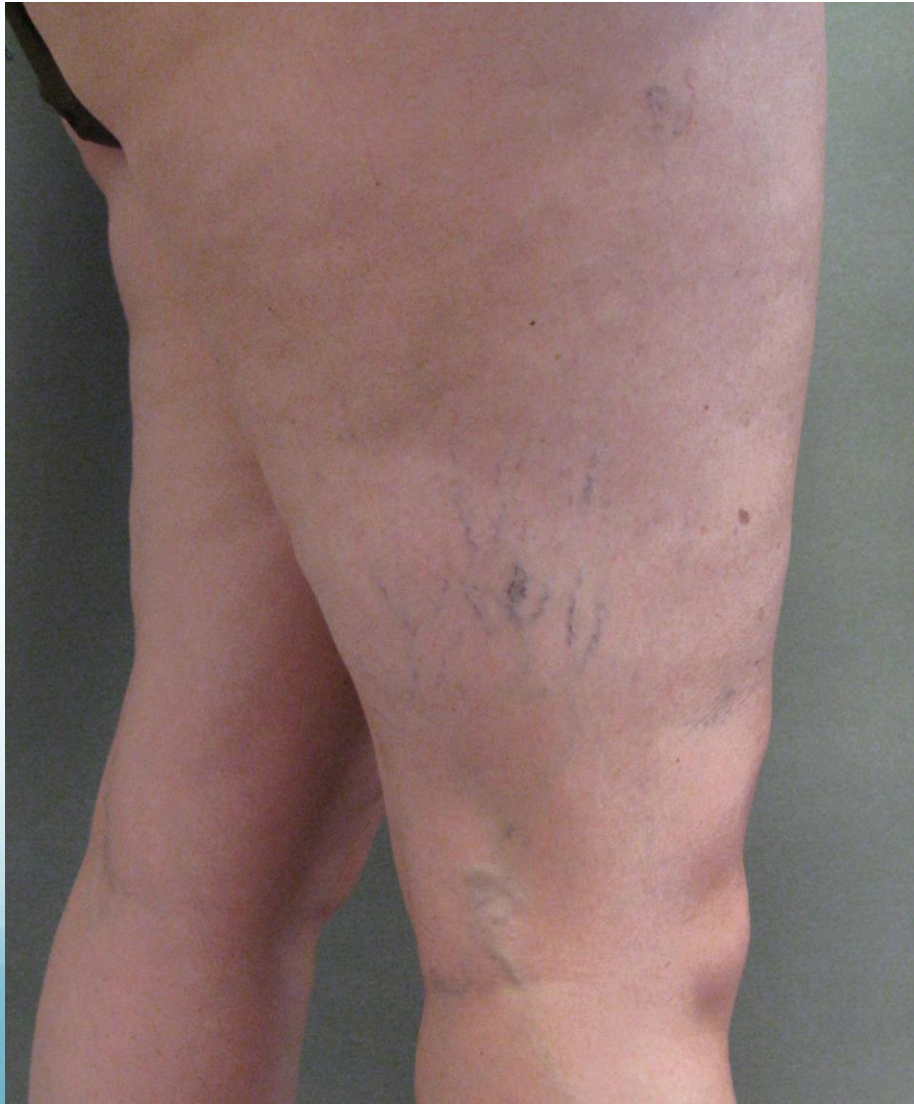- Can be made from a detergent sclerosant
- Increase efficacy of sclerosant in larger vessel
- Bubbles displace blood → increase contact time between sclerosant and vein endothelium
- Lower concentration and volume can be used compared to liquid



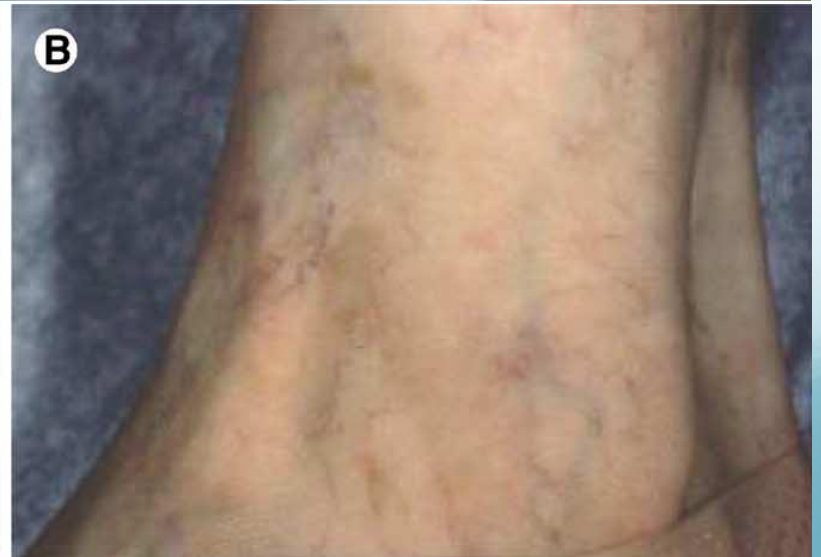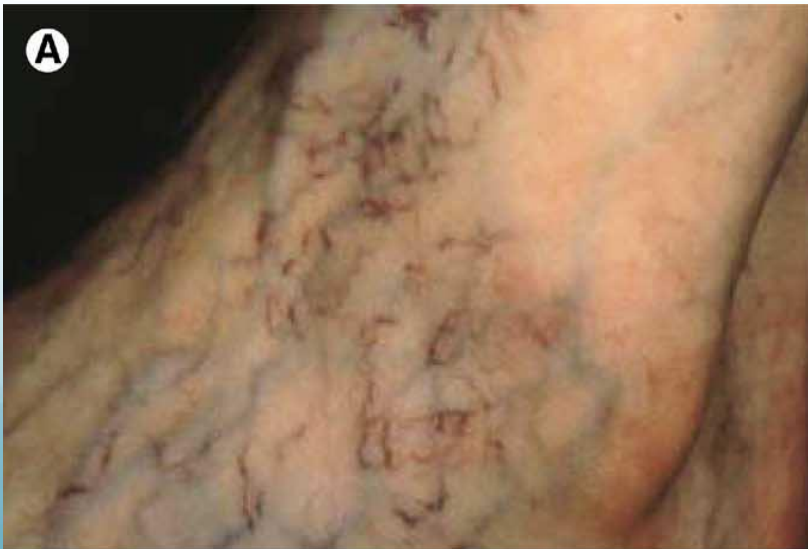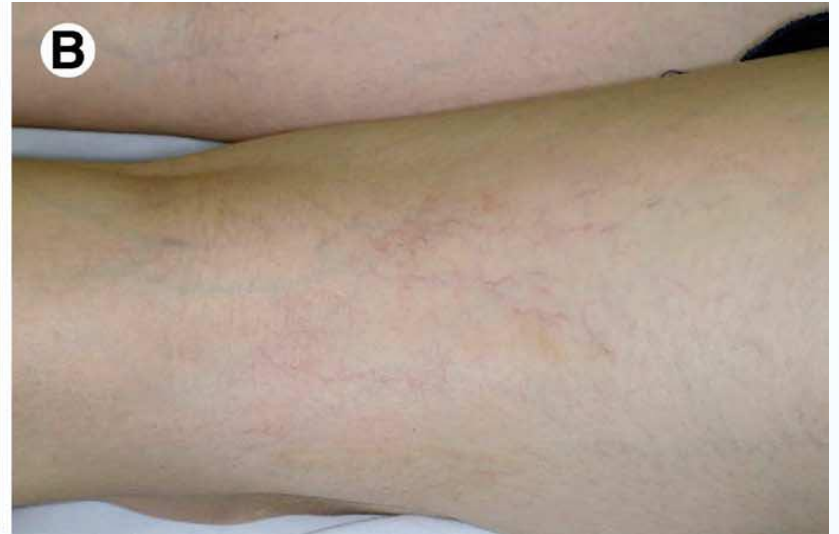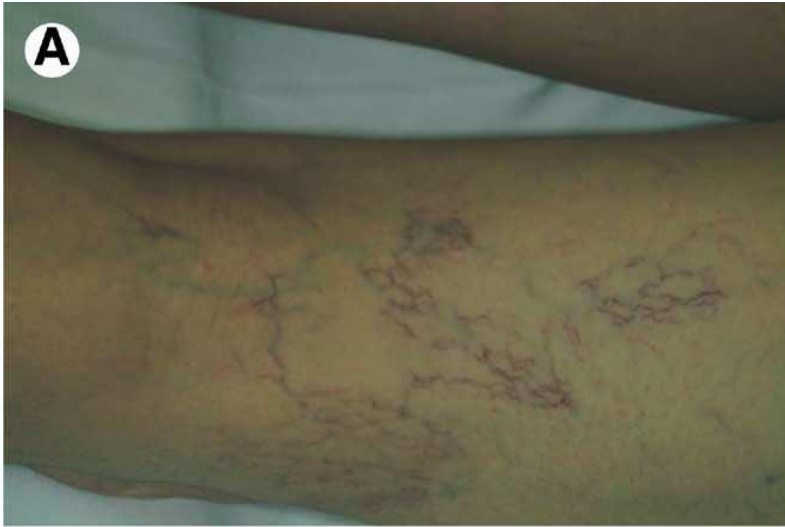Sclerotherapy



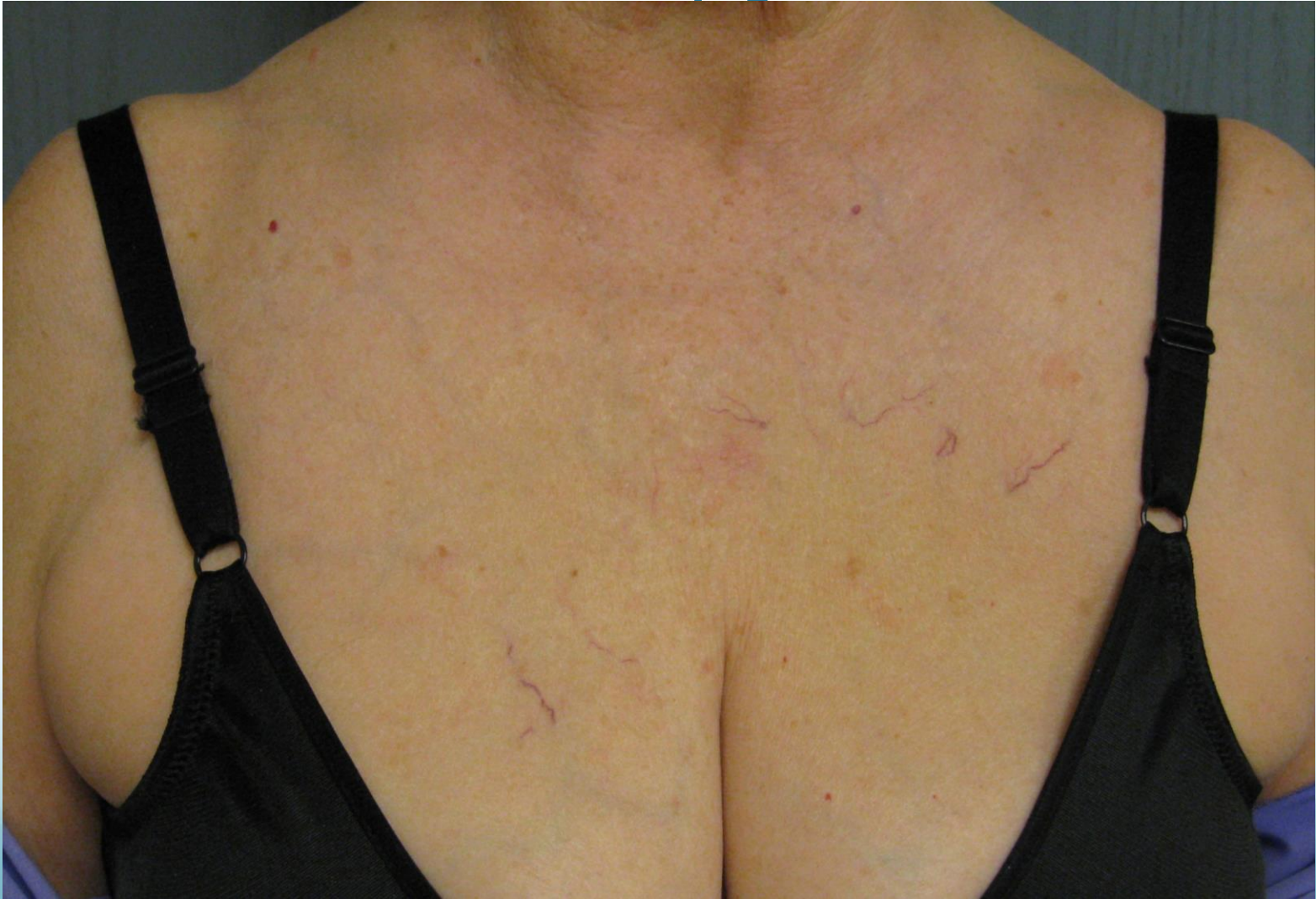Asclera®



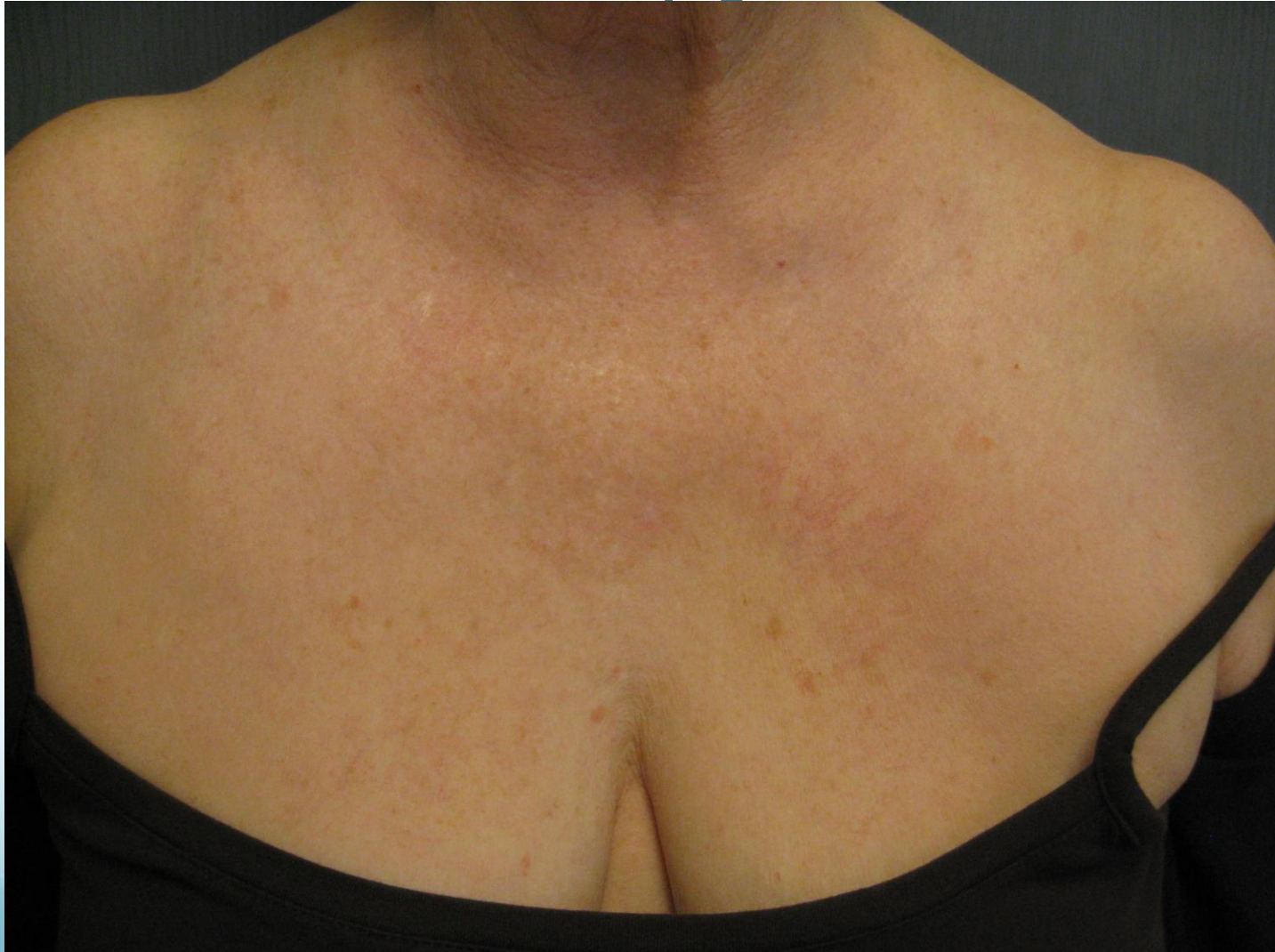Sclerotherapy



Sclerotherapy with IPL

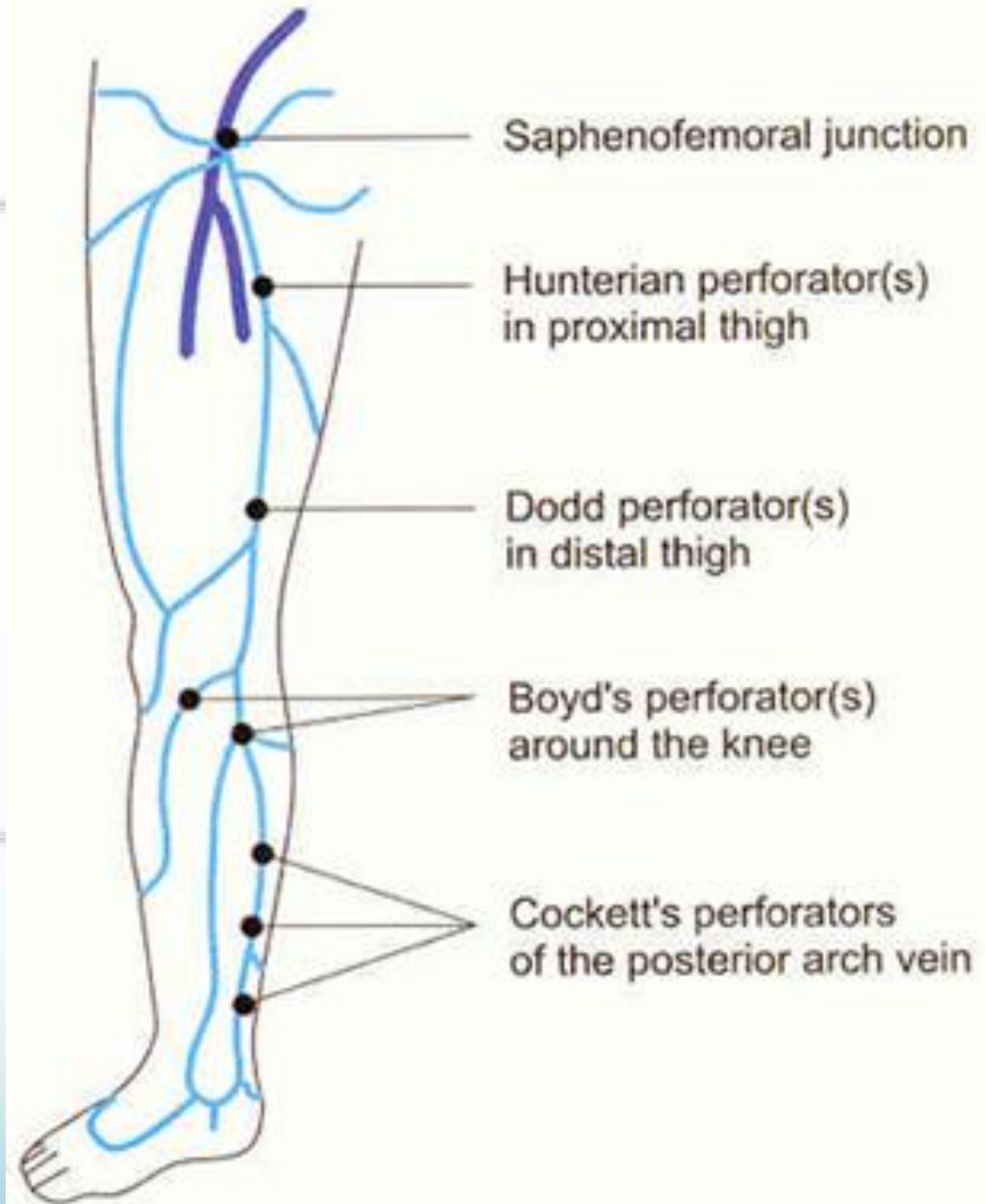
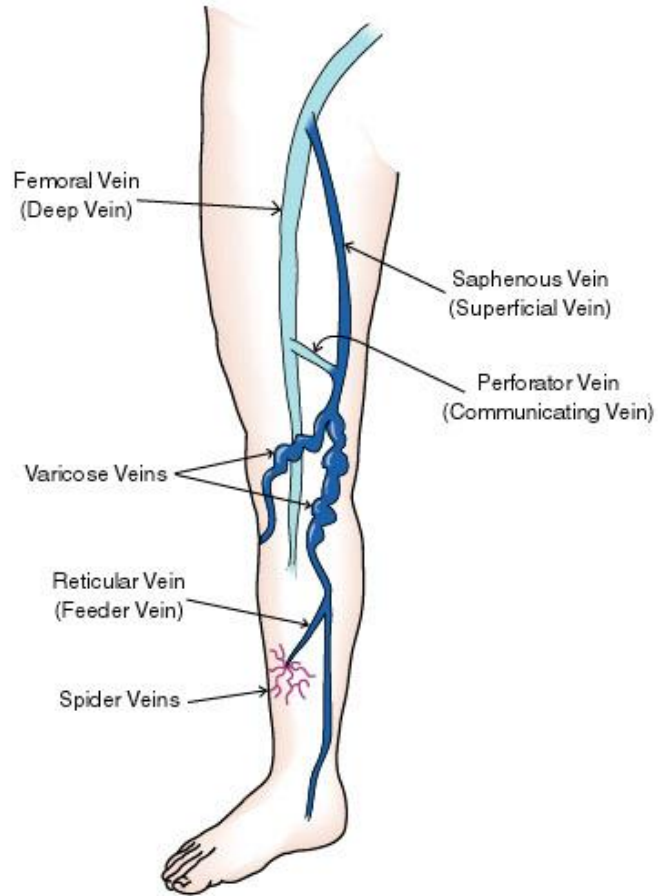


Sclectrotherapy with IPL



Endovenous Laser Ablation

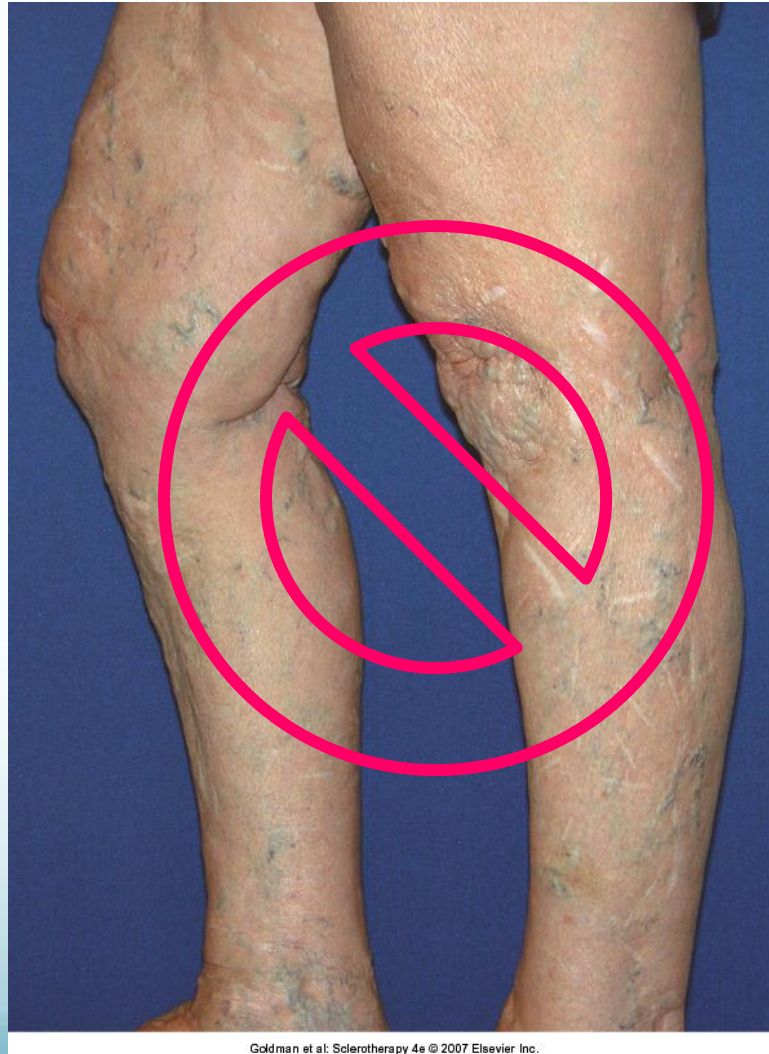Vein Anatomy



Closure of the Great Saphenous Vein

<u>PROCEDURE</u>	<u>ADVANTAGES</u>	<u>DISADVANTAGES</u>
Stripping and Ligation	•Gold standard in the past	•General anesthesia •Neuralgia
Foam Sclerotherapy	•Low cost	•?Efficacy
Electrocoagulation	•Early technique (1950s)	•???
Radiofrequency VNUS Closure	•Minimally invasive	•Cost
Intravascular Lasers •810, 940, 980, 1064, 1320, 1470, 1500		

Traditional Ligation and Stripping with avulsion of varicose tributaries



Endovenous Ablation: Indications

- Ambulatory patients
- Signs:
 - Bulging varicose veins
 - +/- venous insufficiency (edema, dermatitis, pigmentation of lower leg, lipodermatosclerosis, venous ulceration, spontaneous hemorrhage)
- Symptoms:
 - Leg heaviness, aching, fatigue, night cramps, pruritus, restless leg syndrome
- Diagnostic findings:
 - Ultrasound findings: Incompetence of GSV
 - Minimal tortuosity of GSV (permits sheath/catheter placement)

Endovenous Ablation: Contraindications

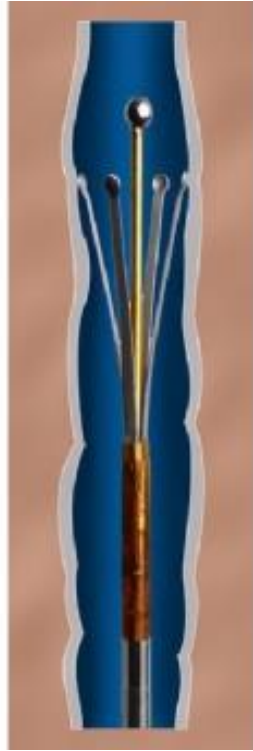
- Absolute
 - Inability to ambulate
 - Implanted device (Pacemaker, Internal defibrillator)
 - Allergy to local anesthetic
- Relative
 - Vein < 2mm diameter
 - Hypercoaguable state
 - Recent venous thromboembolism
 - Leg infection
 - Lymphedema
 - Peripheral arterial insufficiency
 - Poor general health
 - Pregnancy

Radiofrequency Ablation

VNUS Closure[®] Procedure



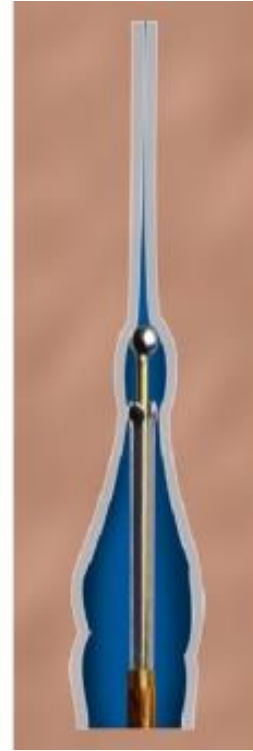**Catheter
inserted
in
refluxing vein**




**Catheter
Positioned,
Electrodes
deployed**



**RF Energy
heats and
contracts
vein wall**



**Catheter
slowly
withdrawn,
closing vein**



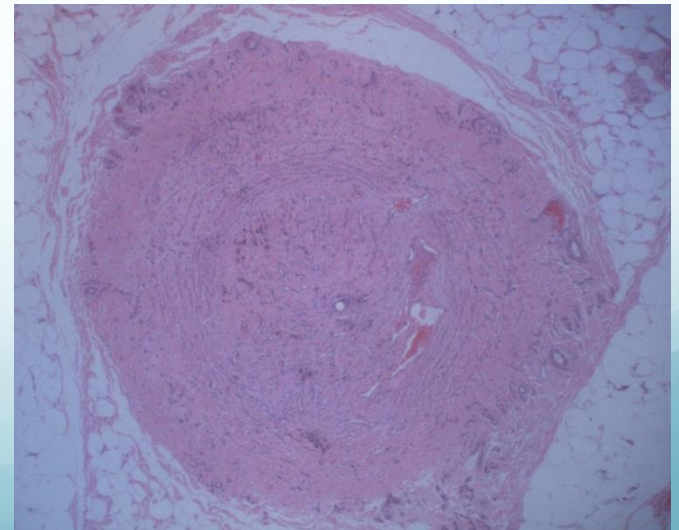
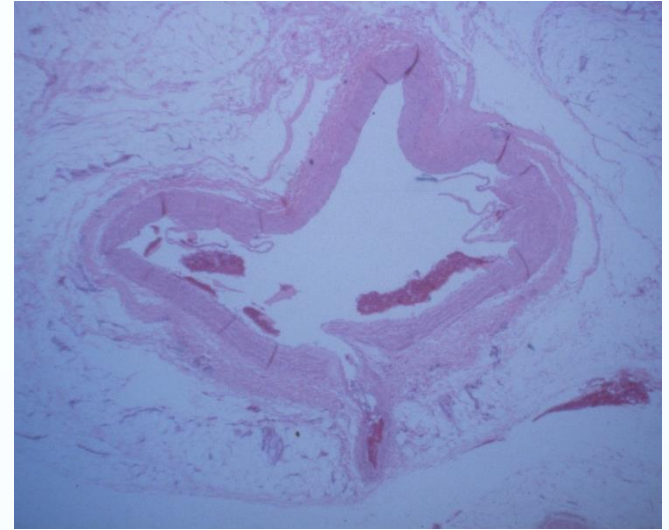
**Denuded
vein
is physically
narrowed**

A Minimally Invasive Alternative to Ligation & Stripping

Collagen Contraction

Controlled heating of the vein wall causes:

- Shortening and thickening of collagen fibers
- Vein lumen diameter shrinkage
- Fibrotic sealing of the vessel

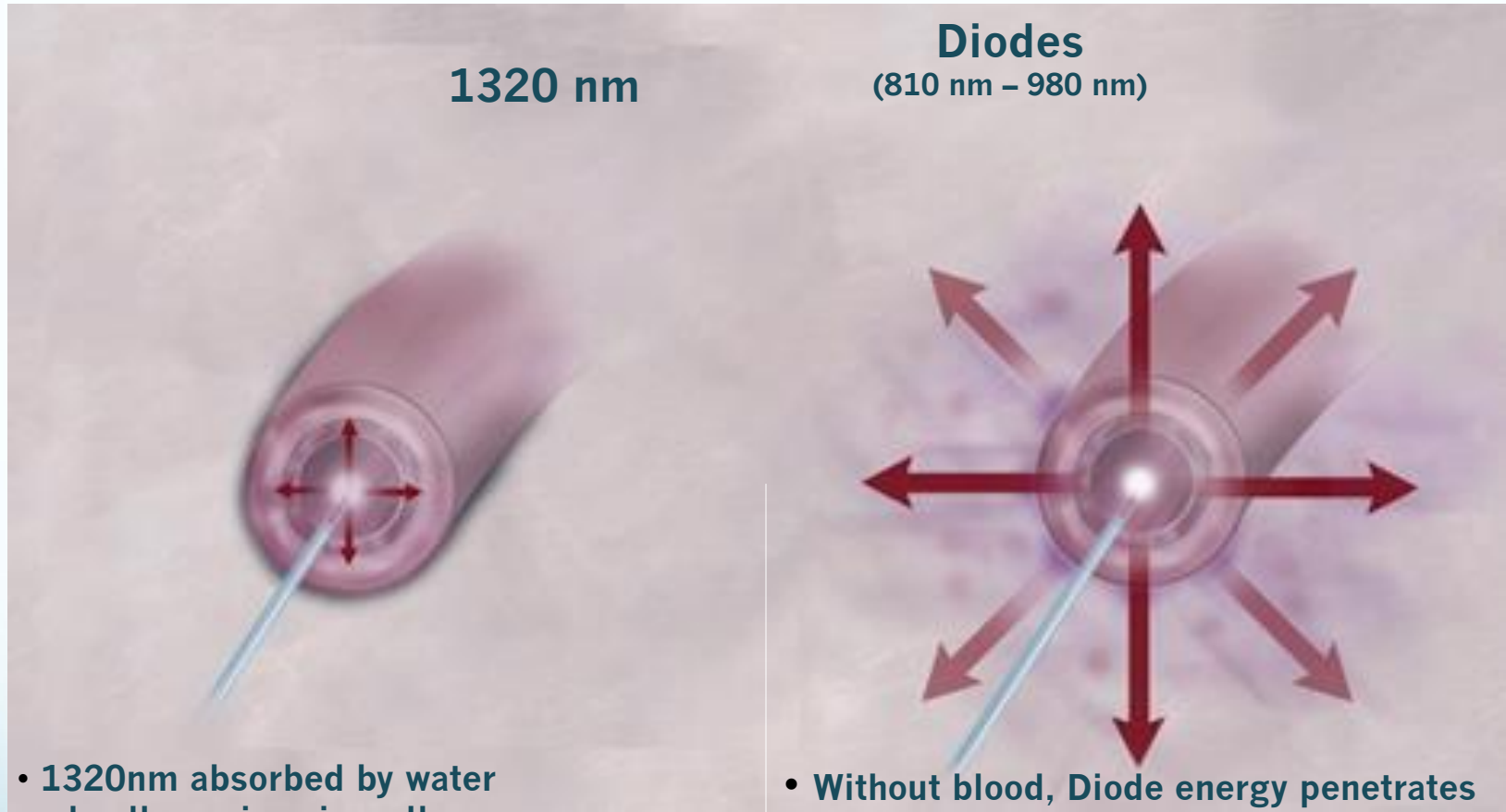


Endovenous Laser Ablation

Endovenous Delivery of Thermal Energy

- Larger veins need more energy
 - More energy = more adverse effects
 - Less energy = recannalization
- Amount of energy dictated by wavelength
 - <1320 nm absorbed by Hb/RBC and conducted to vein wall
 - MOA: laser generates steam by heating blood within vein → temperature rise causes vein wall injury → fibrotic occlusion of vessel wall
 - 1320 nm absorbed by water/endothelial cells
 - Collagen/vessel wall injured directly rather than by heating blood

1320nm vs. Diodes



1320 nm

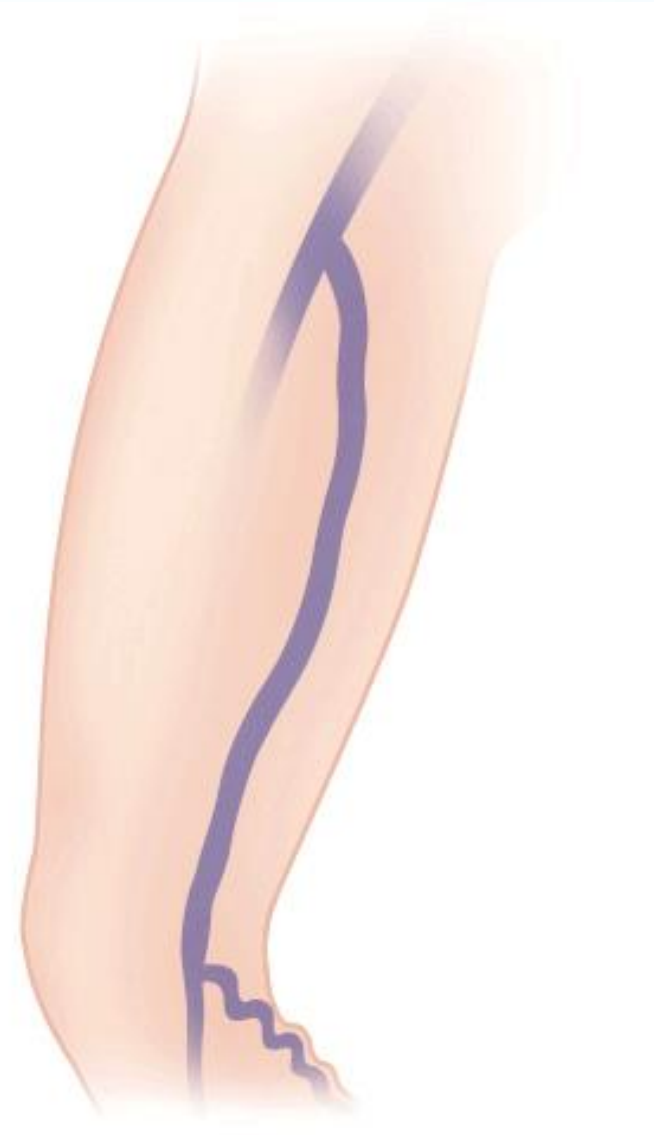
Diodes
(810 nm - 980 nm)

- 1320nm absorbed by water and collagen in vein wall
- Gentle heating contracts vein leading to closure
- Minimal to no post-op pain and bruising

- Without blood, Diode energy penetrates through vein wall
- With blood present, high blood absorption by Diodes can cause extremely high temperatures and vein rupture
- Can cause pain, bruising and post-op complications

EVLT Technique

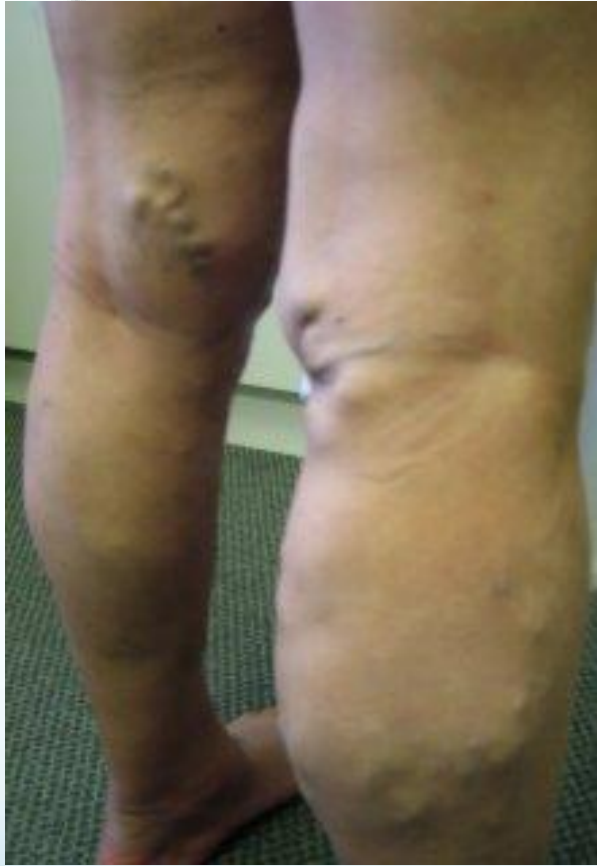- GSV identified through U/S duplex or Doppler
 - U/S guided
 - External marking with manual identification
- Anesthetize access point; Venipuncture of GSV with U/S guidance
- Guide wire (confirm placement), introducer sheath with dilator over guide wire
- Guide wire and dilator removed, laser threaded through sheath to insertion of SFJ, sheath removed
- Tumescent anesthesia (avg. 700ml) to fill fascial sheath enclosing GSV
- Slow withdrawal of laser tip (2cm from SFJ)
- +/- ambulatory phlebectomy



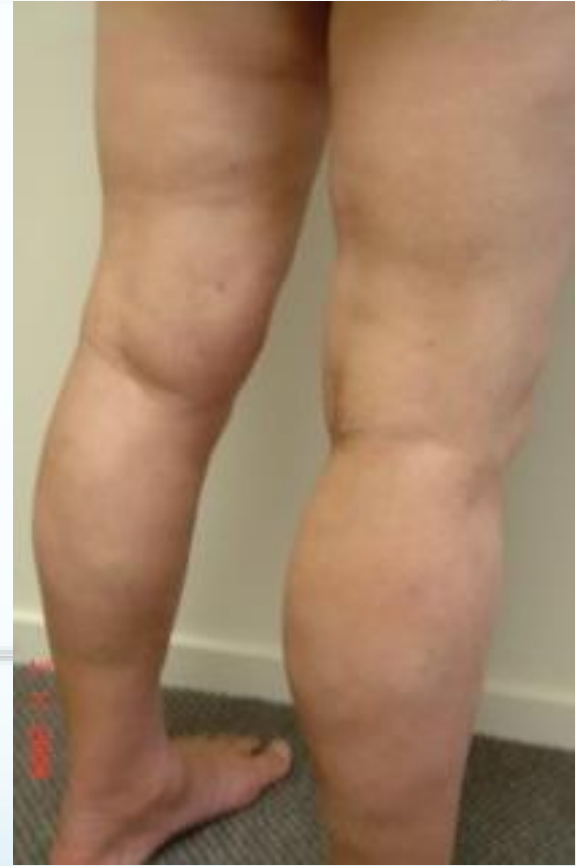Outcomes of EVLT Treatment

- 90-100% closure at 12 month follow-up according to clinical studies
 - 83-90% at 2-5 years for RF ablation (VNUS)
- >70% patients resume daily activities within 24 hours
- Compression stockings typically worn for 1 week

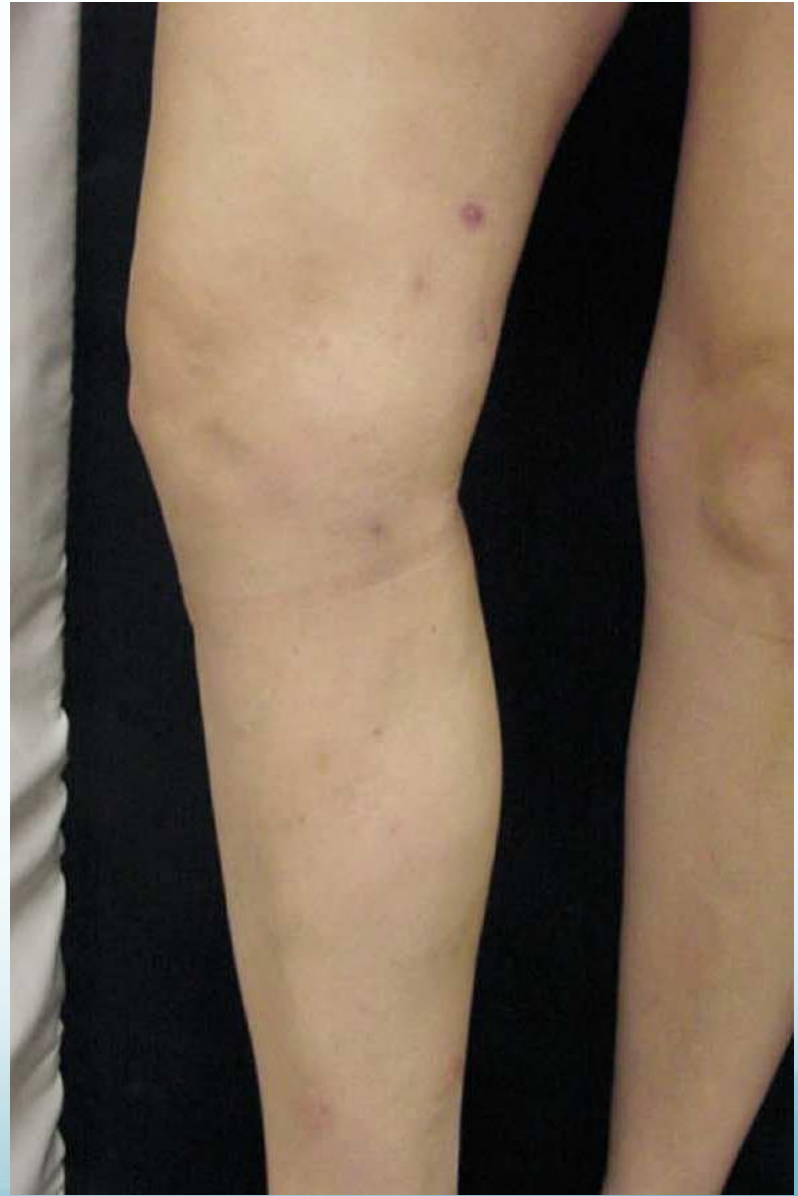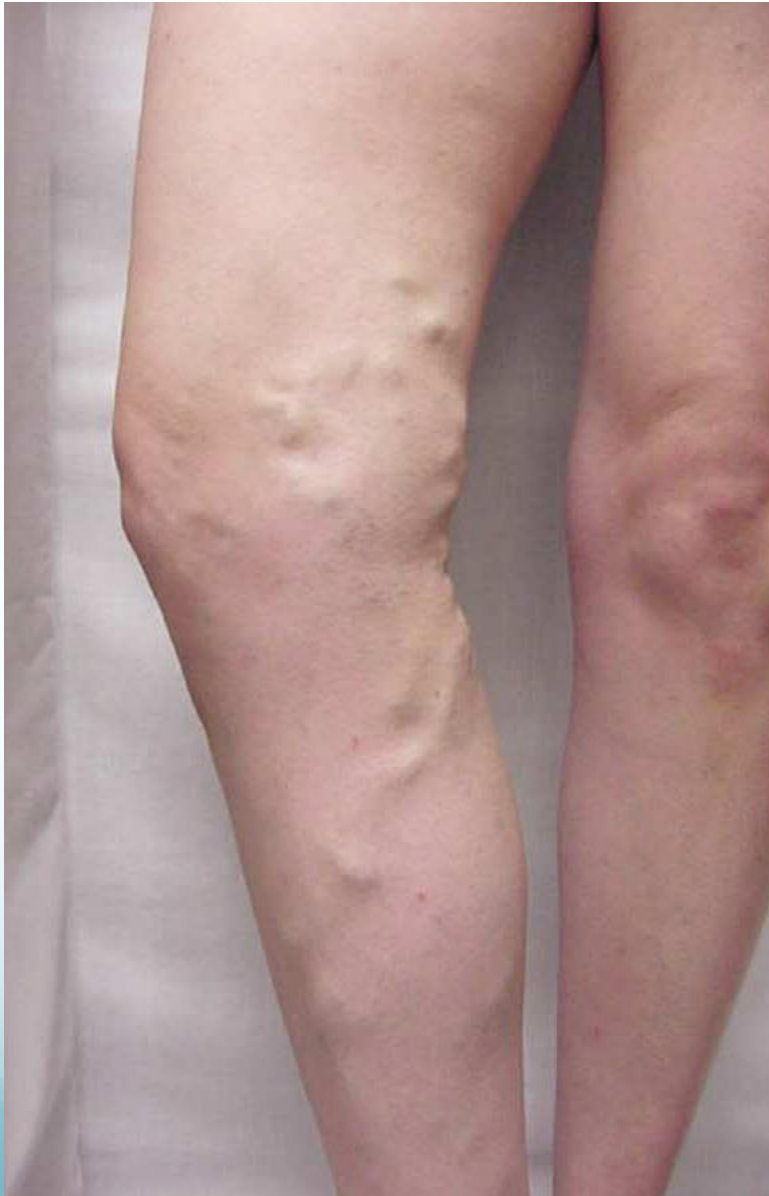1320nm CTEV to GSV

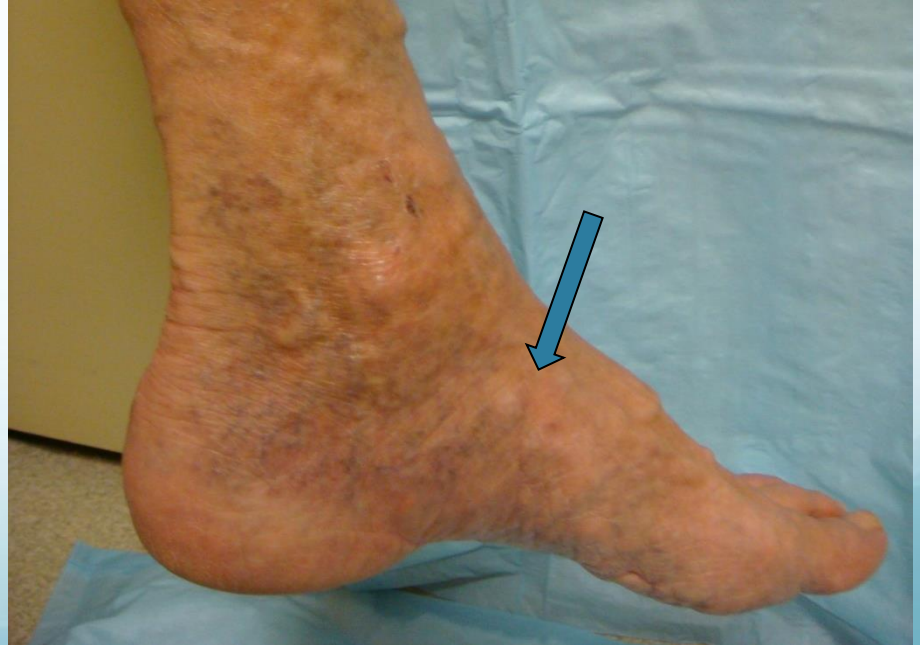
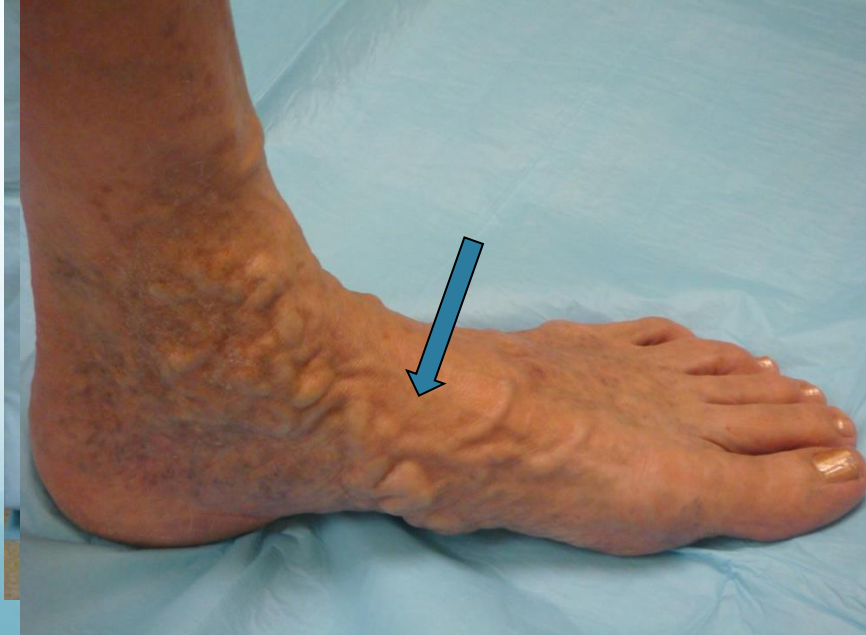
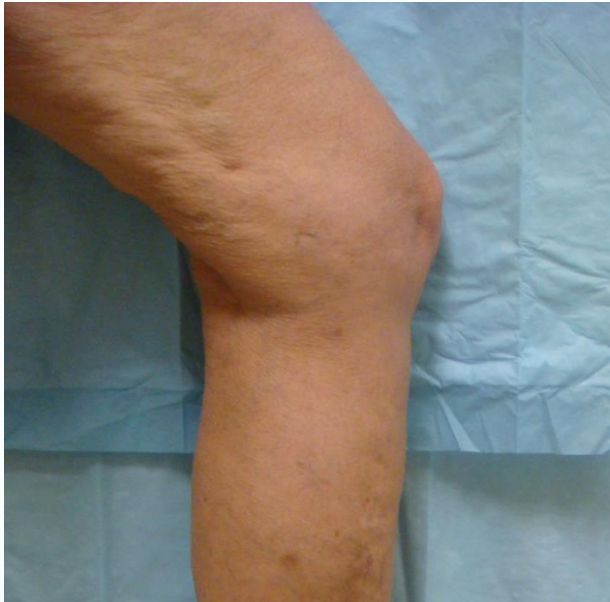Pre-Op



4 months post-op

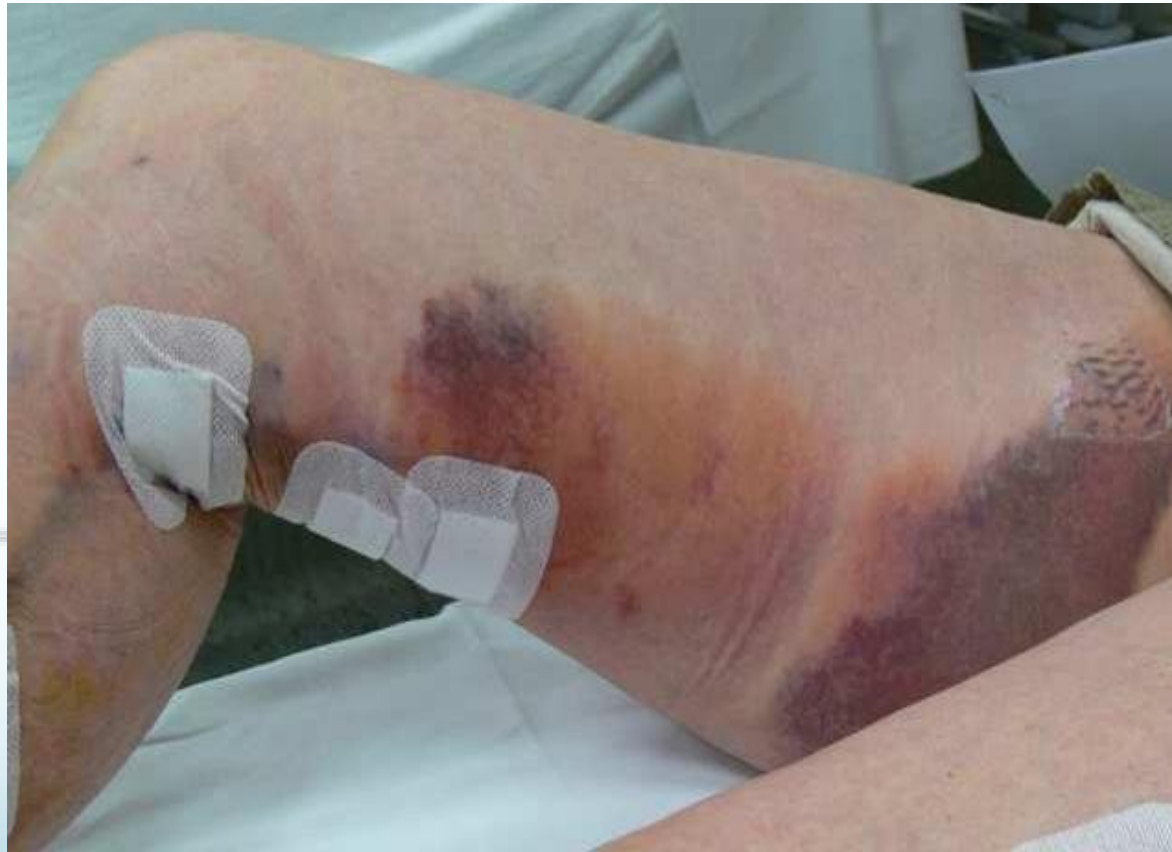



Possible Adverse Events of EVLT

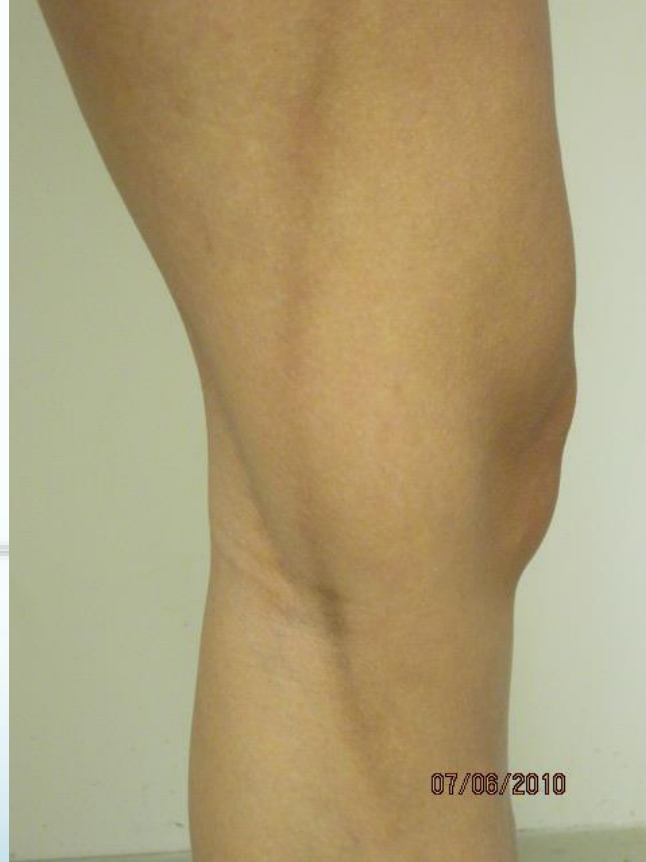- Pain/tenderness 72 hours post-op
- Bleeding: bruising or hematoma
- Swelling
- Lymphocele
- Cellulitis
- Superficial venous thrombosis
- Hyperpigmentation
- Skin ulceration
 - Thin patients, males, superficial GSV
- Paresthesias

Purpura following EVLT Procedure



The Use of a New Endovenous Laser Device: Results of the 1500 nm Laser.
Vuyksteke, et al Las Surg Med 2009 (in press)

Diomed 4 months post-op: Hyperpigmentation



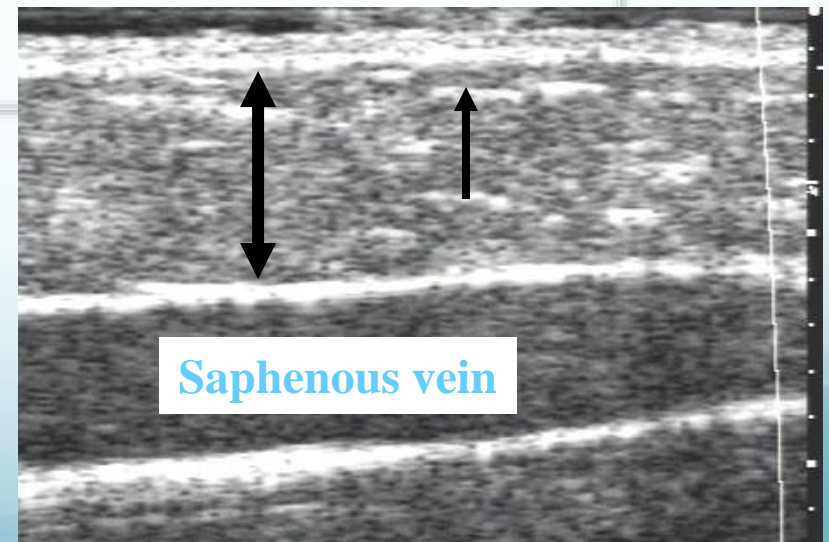
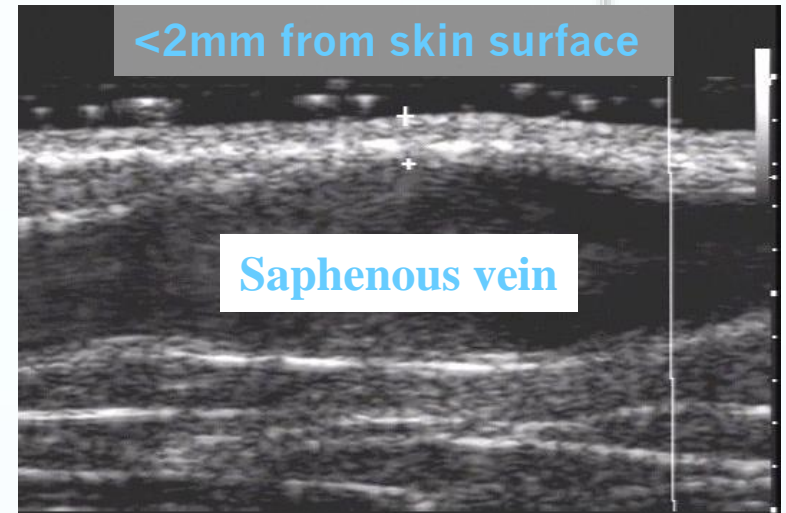
Avoiding Skin Burns

Probable risk factors:

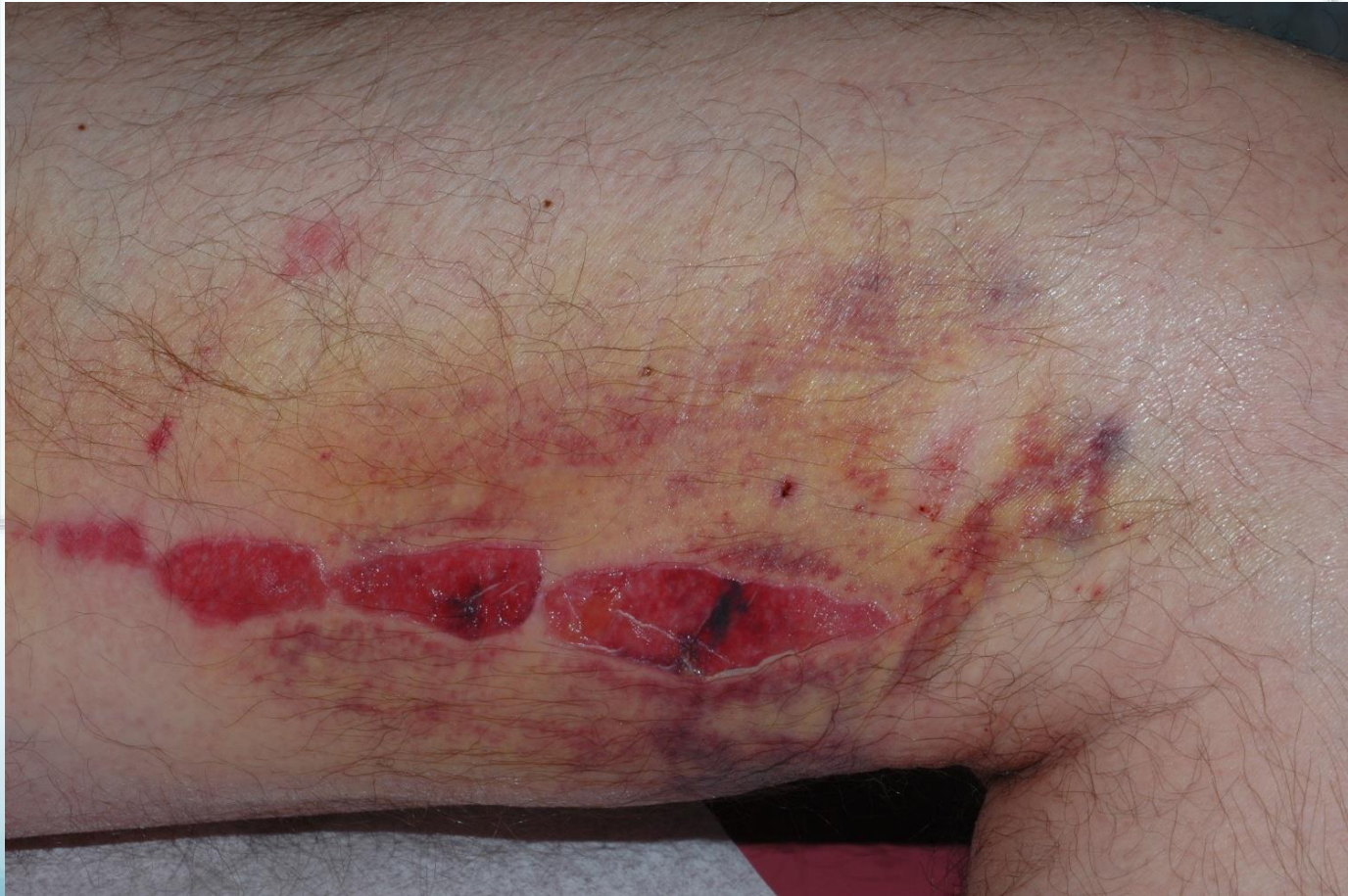- Males
- Thin or muscular legs
- Vein <10 mm of skin

Prevention

- Saline or dilute lidocaine infiltration
 - Heat sink effect
 - Increases distance between vein & dermis
- Tumescence anesthesia



Cutaneous Burn from Diomed 810nm EVLT @ 48 Hours



Good luck!

www.acls-algorithms.com